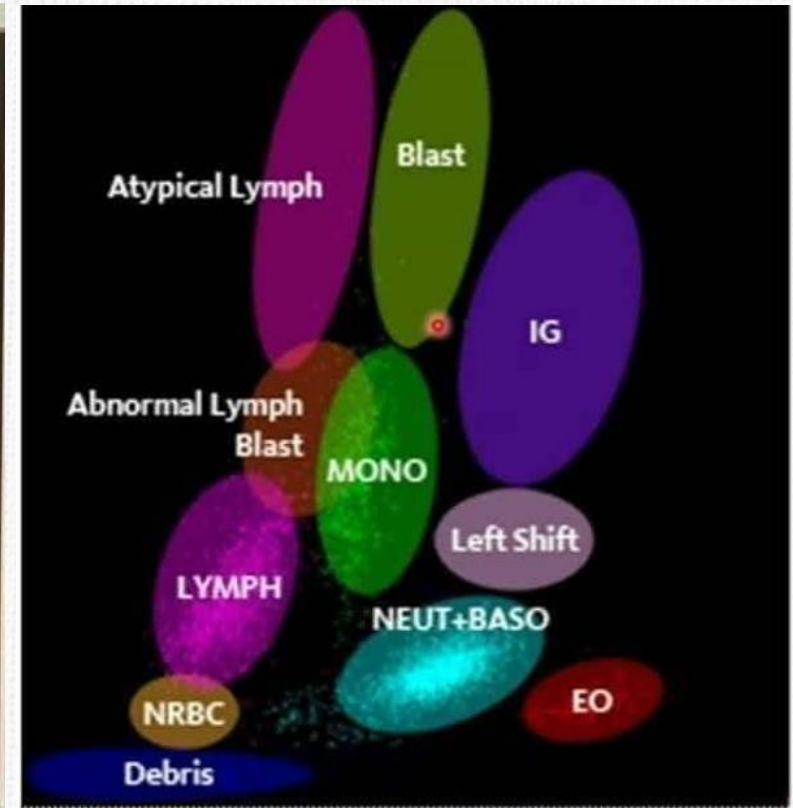
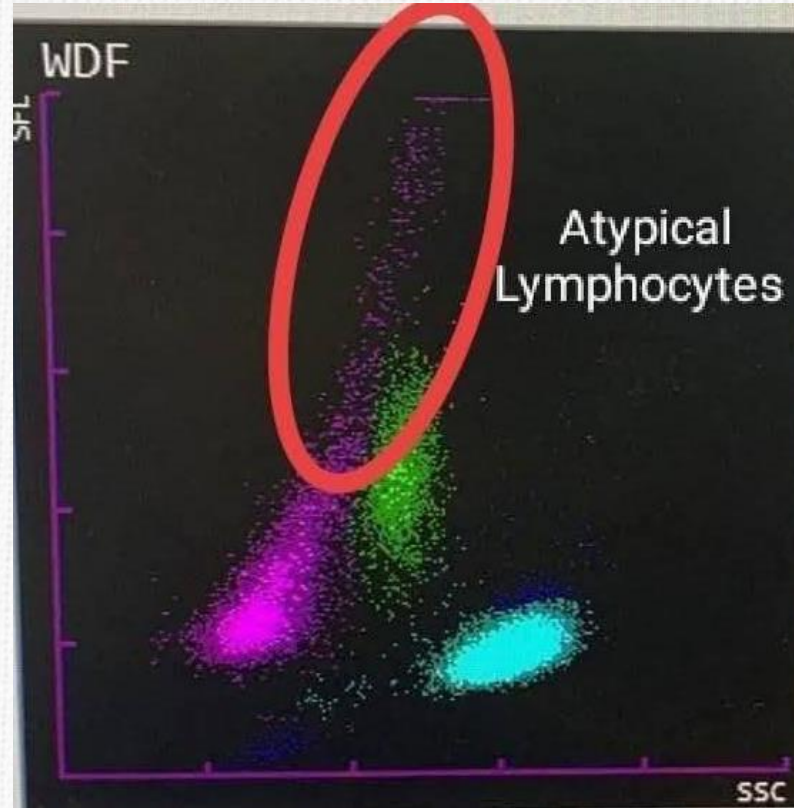
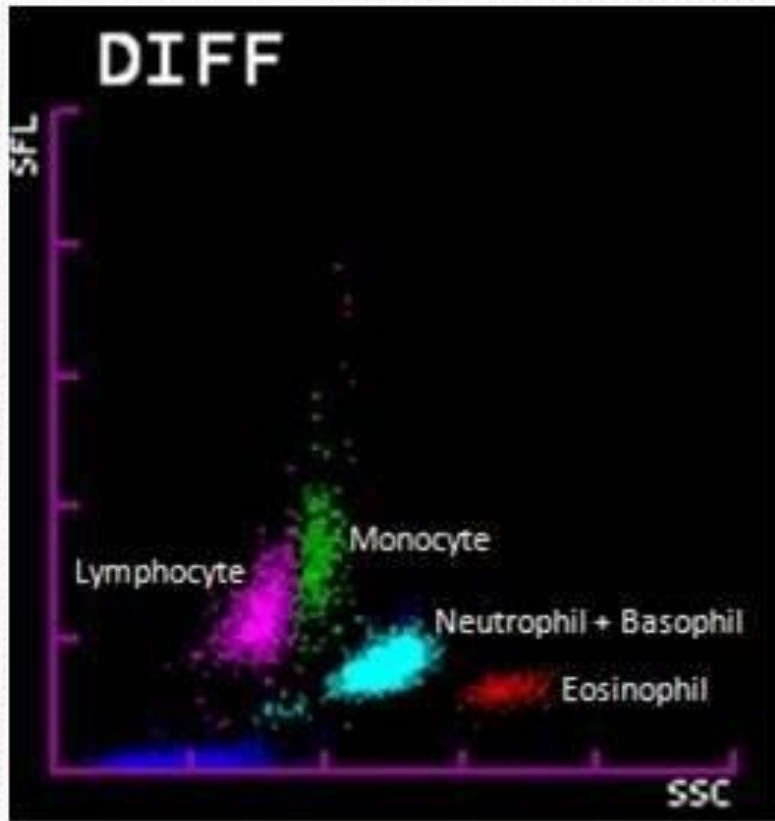
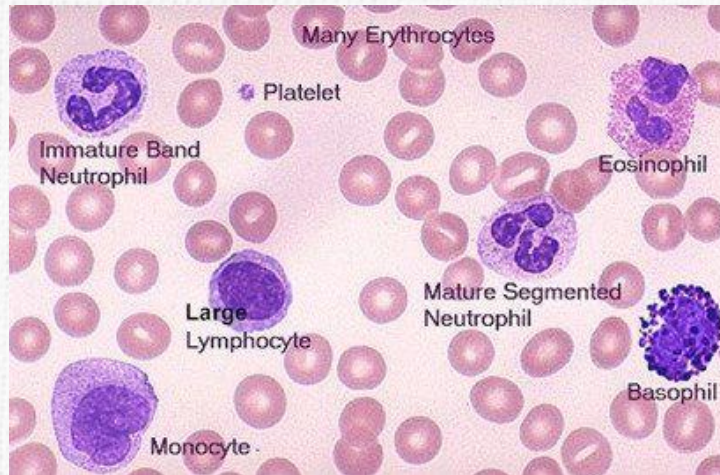


Ανίχνευση Παθολογικού Πληθυσμού στον Αναλυτή

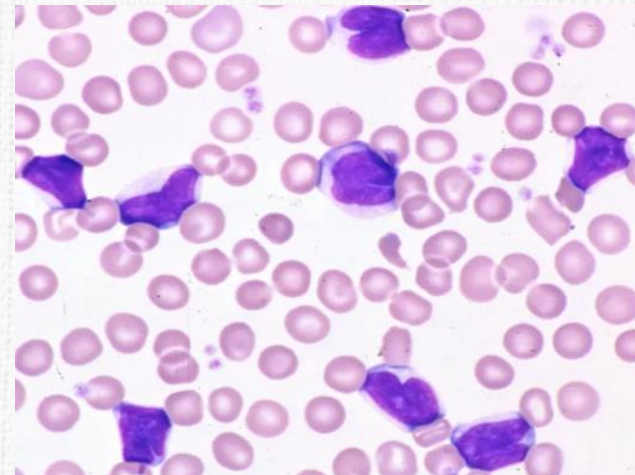


Καθημερινά Δείγματα

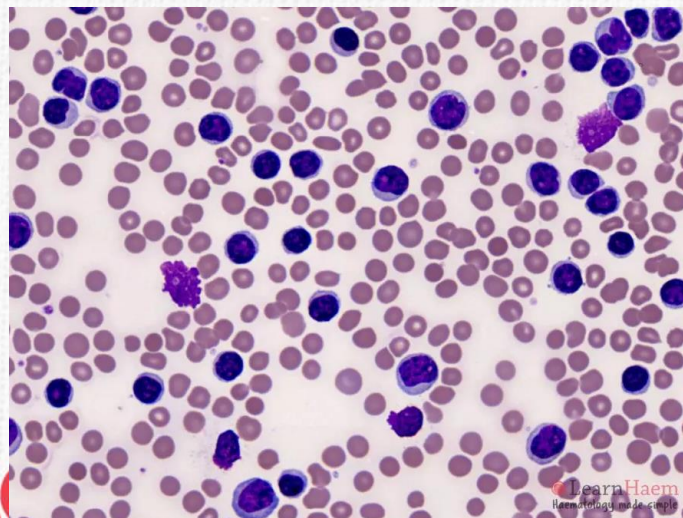
Normal peripheral blood



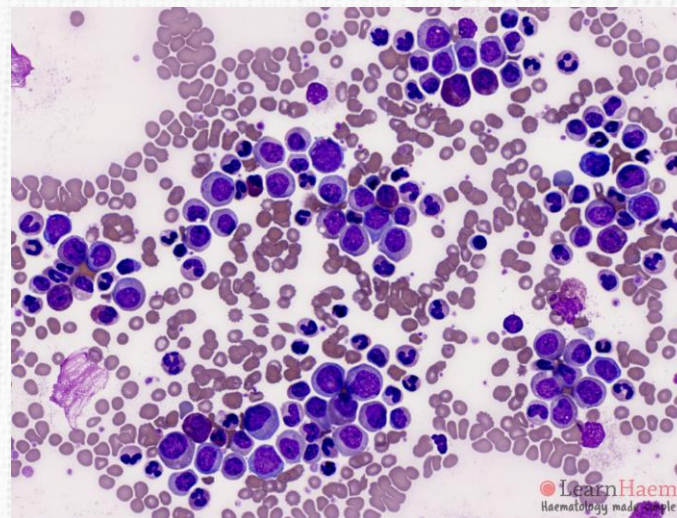
Reactive lymphocytosis



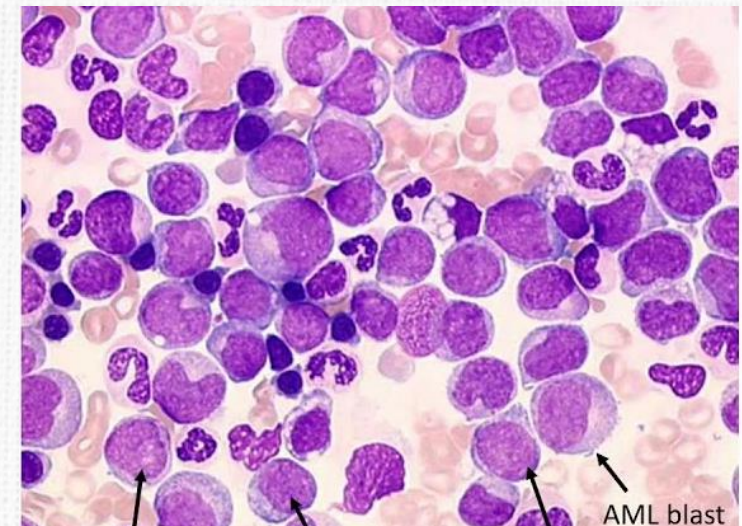
Chronic lymphocytic leukemia (CLL)



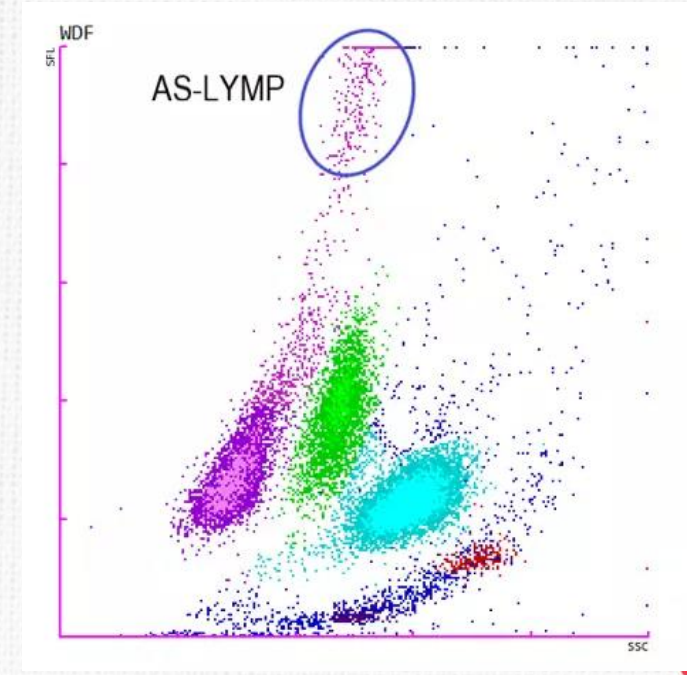
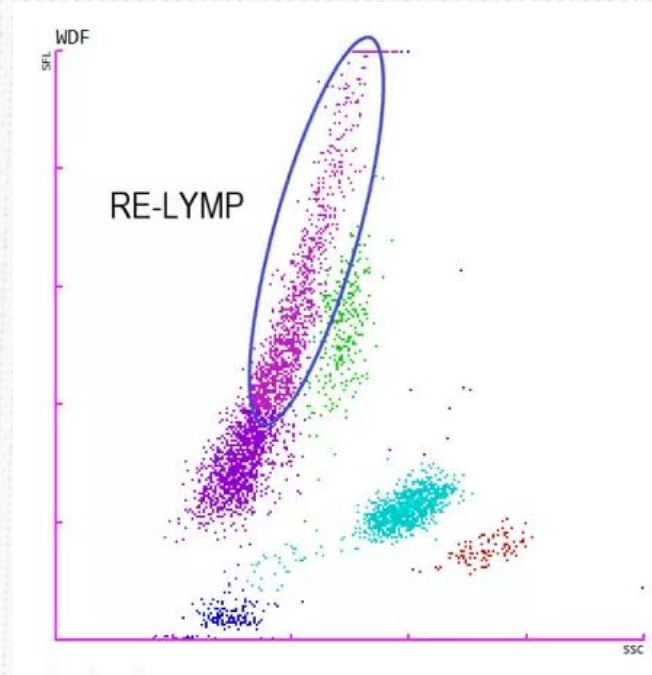
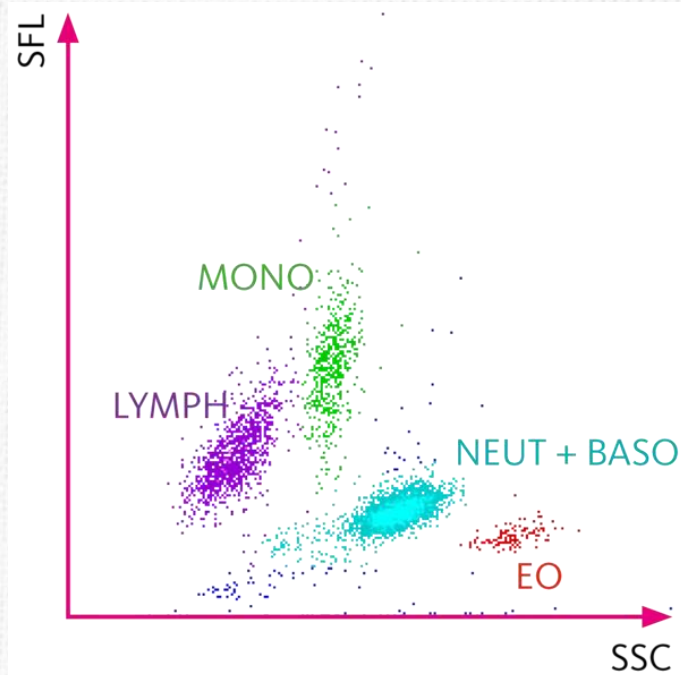
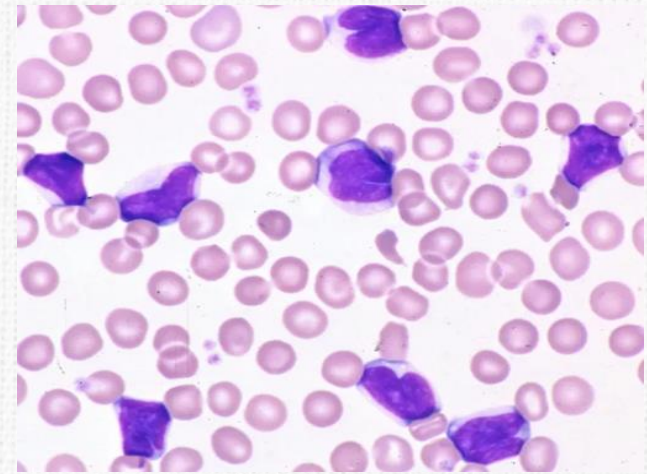
Chronic myelocytic leukemia (CML)



Acute myeloblastic leukemia (AML)



Αναγνώριση Ενεργοποίησης Λεμφοκυττάρων



Φυσιολογικός πληθυσμός

Αντιδραστικά λεμφοκύτταρα
(reactive lymphocytes)

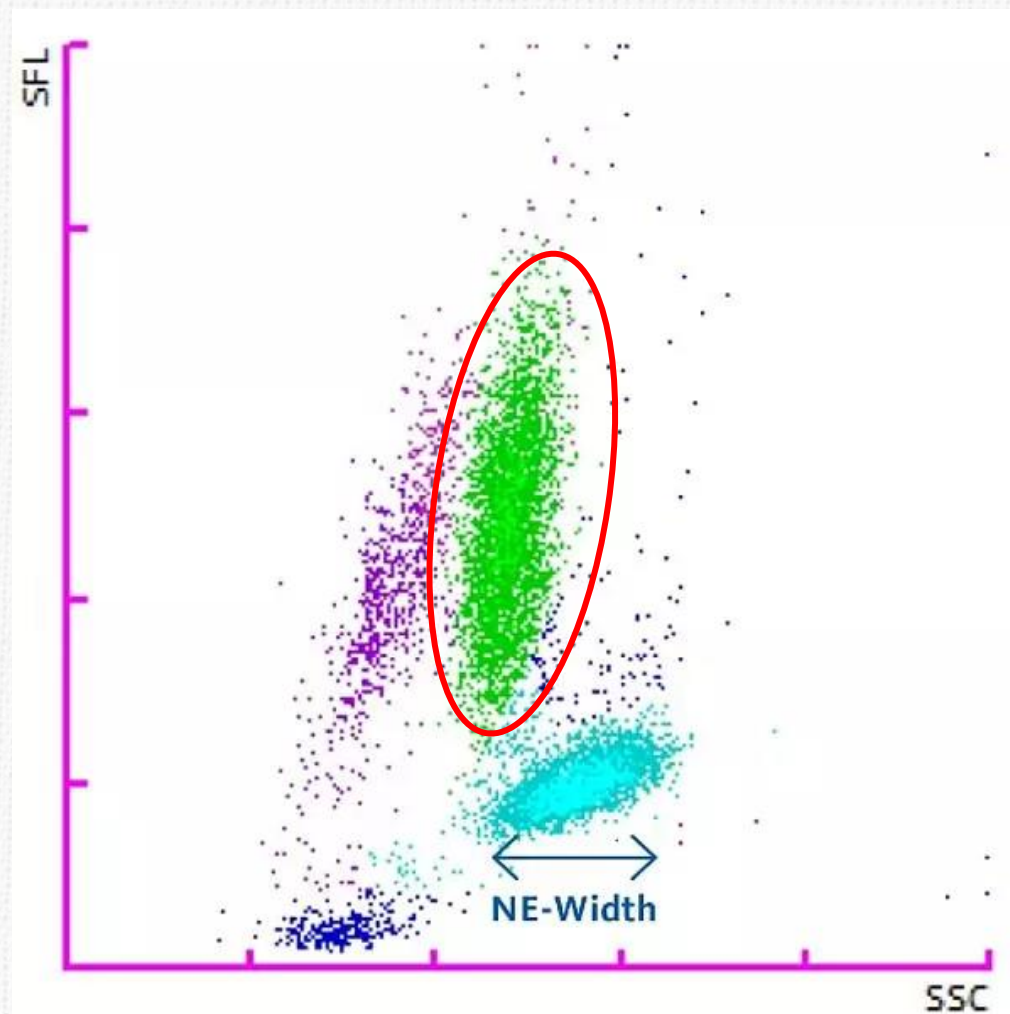
Πλασματοκύτταρα (Antibody
Synthesizing lymphocytes)

Από το «Δεν βλέπω» στο «Ξεχωρίζω»

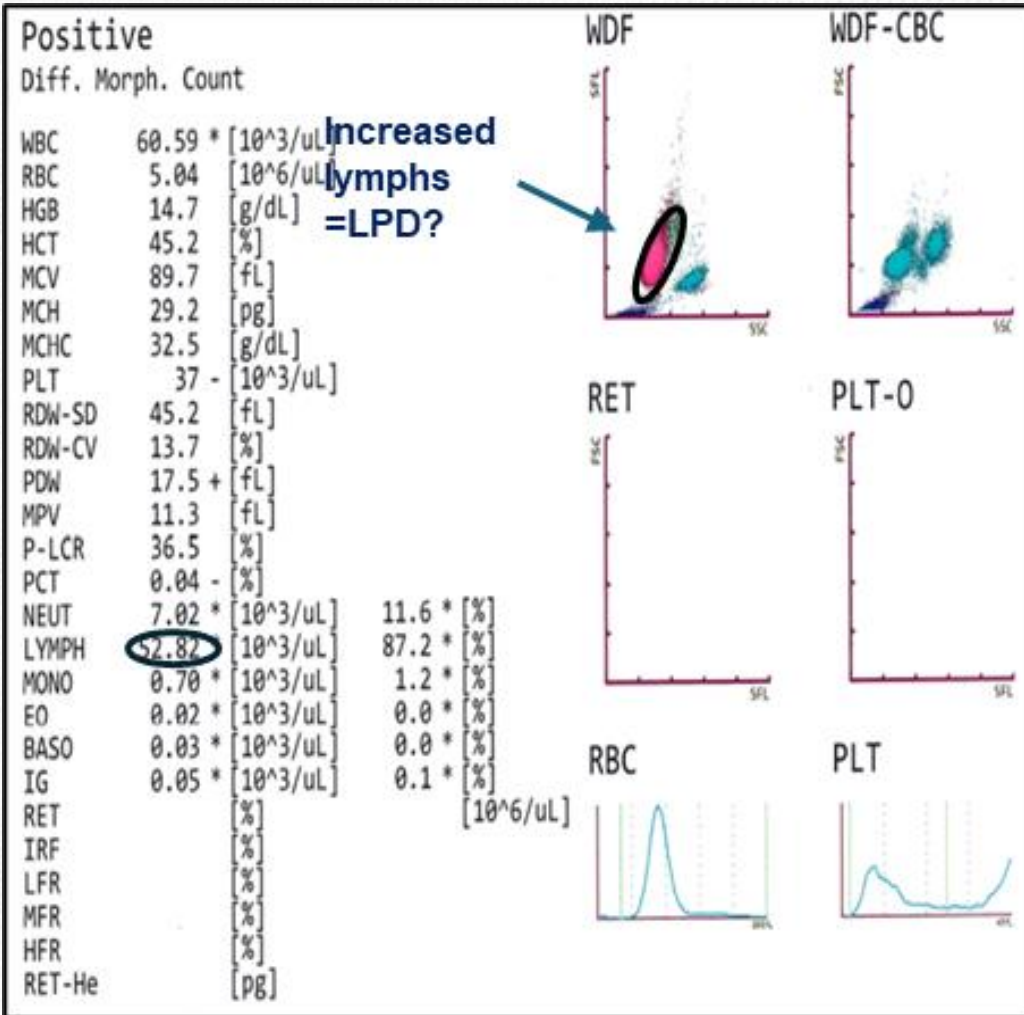
Δεν βλέπω

Βλέπω

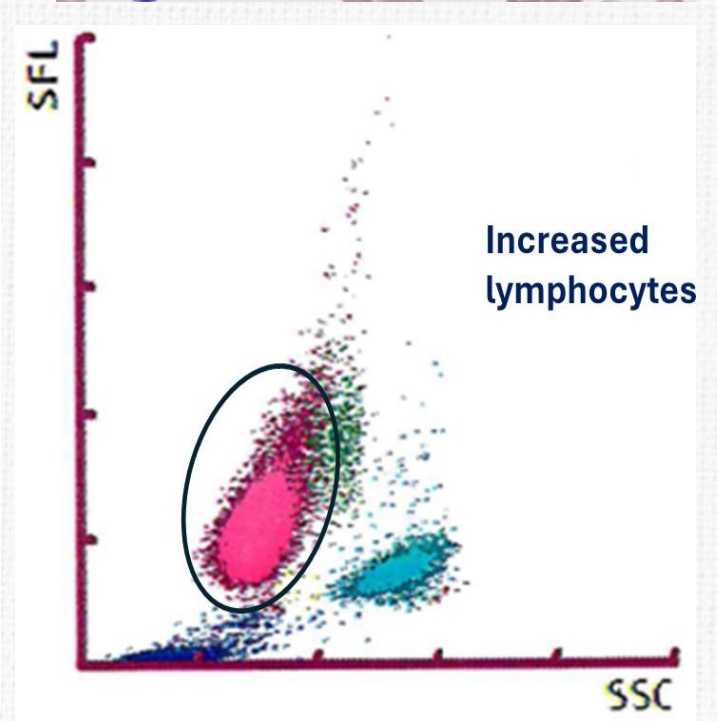
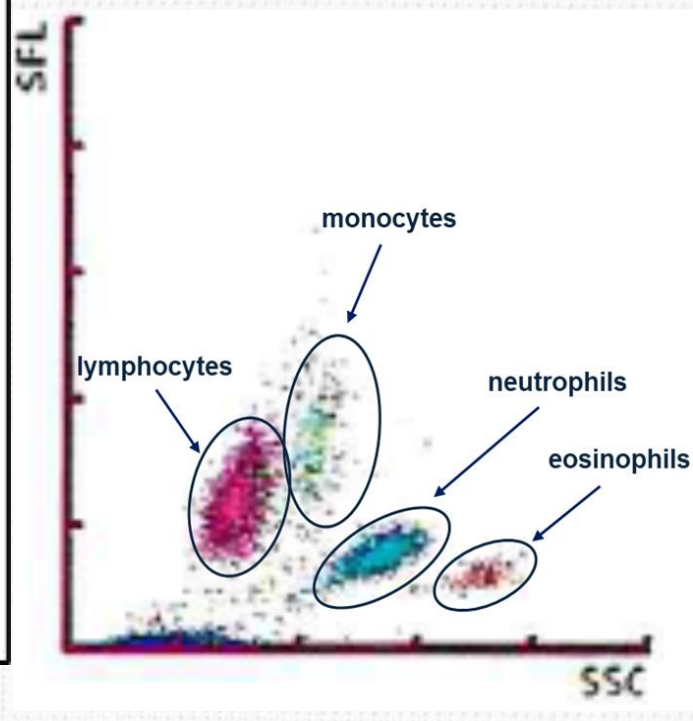
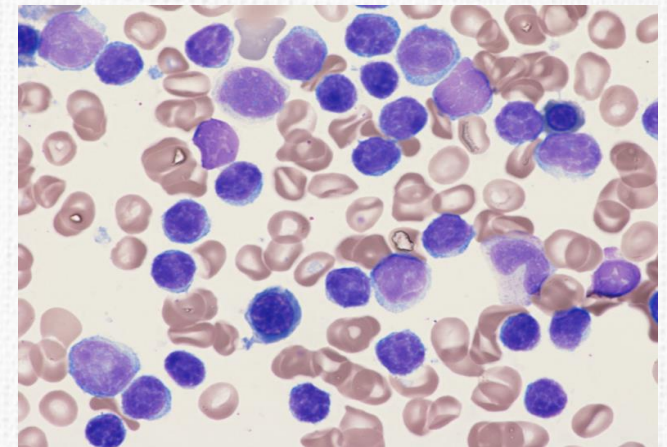
Ξεχωρίζω




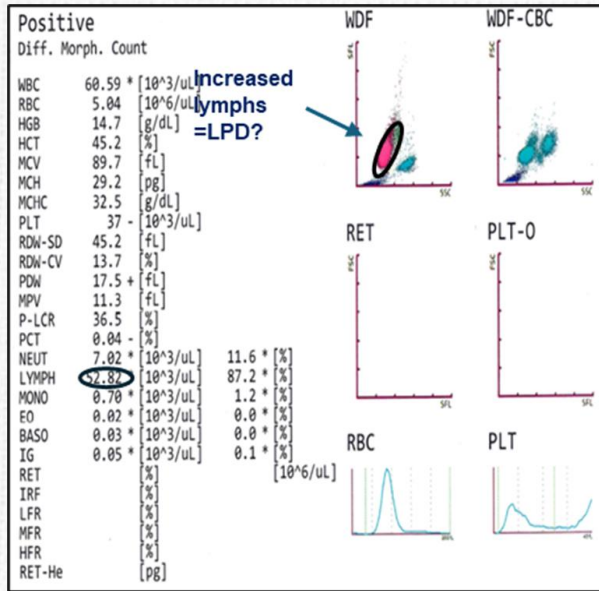
Λεμφοκυττάρωση (ΧΛΛ)



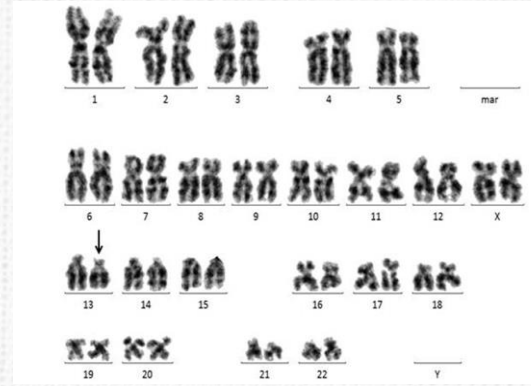
- **CBC** Αυξημένα λευκά, 60,590/ μl,
- Αυξημένα λεμφοκυττάρω 52,820/ μl
- Κατανομή ιστογράμματος?
- **Μορφολογία:** Αυξημένα ώριμα λεμφοκύτταρα



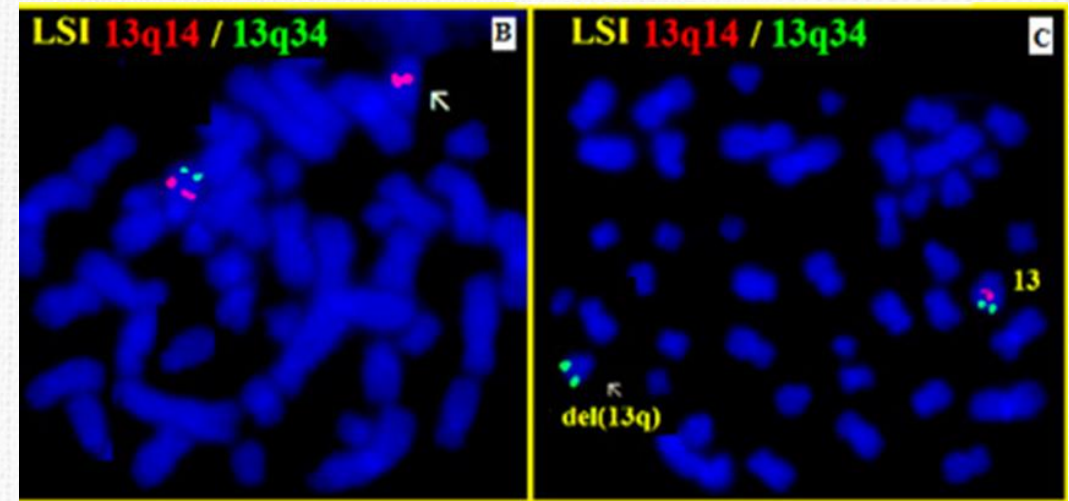
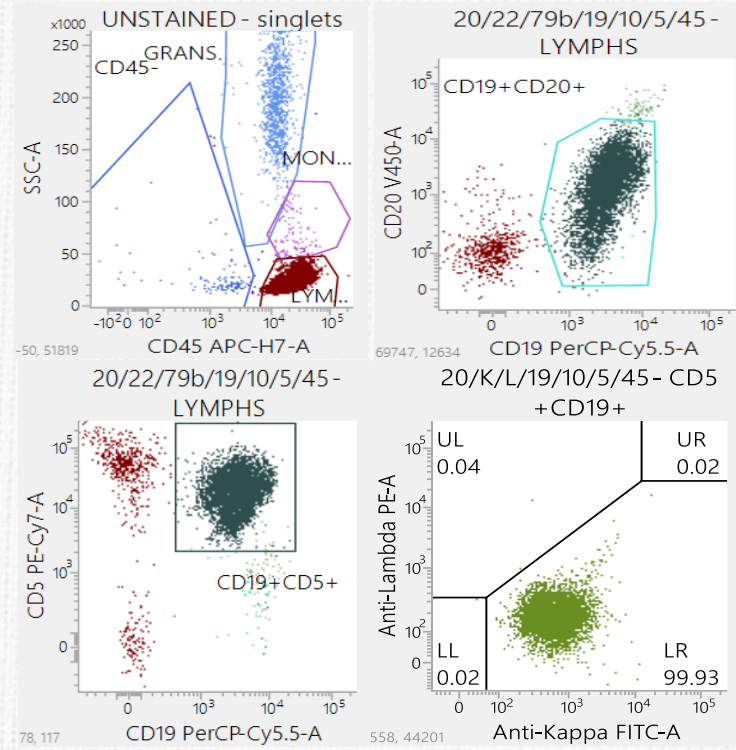
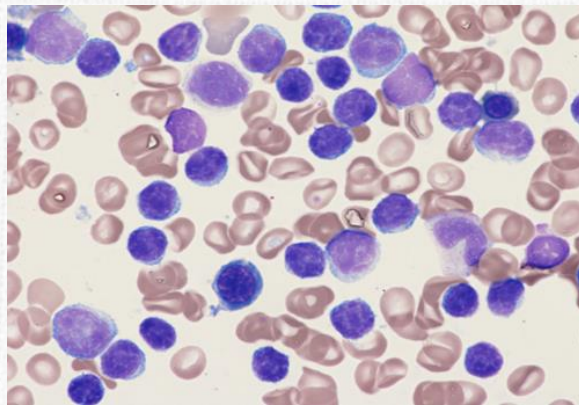
Μαθαίνω να Ξεχωρίζω = Η Αρχή της Διάγνωσης



ΧΛΛ
Ανοσοφαινότυπος:
 CD5+, CD19+,
 CD20d+, CD23+,
 Καππα+



Prognosis:
 IGHV Mutational Status
 TP53 Mutation
CLL FISH:
 • 13q14 deletion,
 • 17p deletion (TP53)



Χρόνια Λεμφοκυτταρική Λευχαιμία (CLL)



Χρόνια Μυελογενής Λευχαιμία (CML)

Positive
Diff. Morph. Count

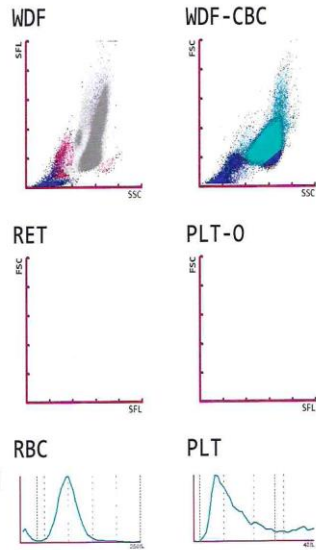
WBC &	612.81	[10 ³ /uL]
RBC	1.96	[10 ⁶ /uL]
HGB	6.8	[g/dL]
HCT	18.6	[%]
MCV	97.9	[fL]
MCH	35.8	[pg]
MCHC	36.6	[g/dL]
PLT	142	[10 ³ /uL]
RDW-SD	66.9	[fL]
RDW-CV	18.9	[%]
PDW	19.3	[fL]
MPV	12.5	[fL]
P-LCR	44.5	[%]
PCT	0.19	[%]
NEUT	562.84	[10 ³ /uL]
LYMPH	12.76	[10 ³ /uL]
MONO	33.94	[10 ³ /uL]
EO	0.76	[10 ³ /uL]
BASO	2.51	[10 ³ /uL]
IG	273.23	[10 ³ /uL]
RET		[10 ⁶ /uL]
IRF		[%]
LFR		[%]
MFR		[%]
HFR		[%]
RET-He		[pg]

WBC-BF	[10 ³ /uL]
RBC-BF	[10 ⁶ /uL]
MN	[10 ³ /uL]
PMN	[10 ³ /uL]
TC-BF#	[10 ³ /uL]

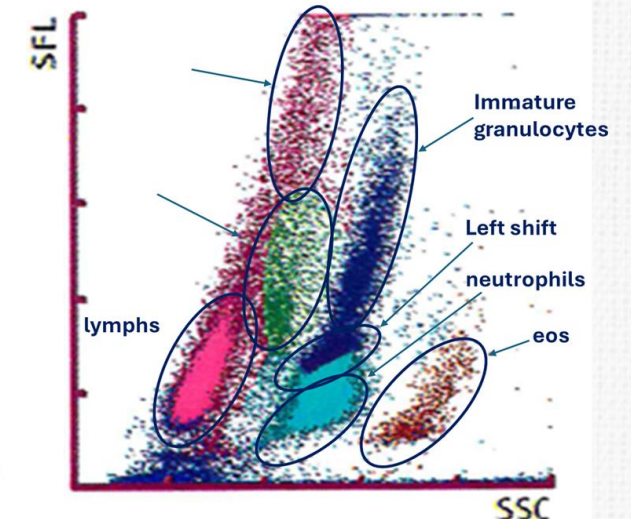
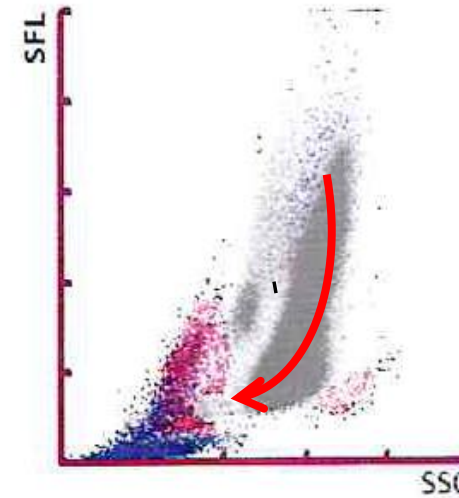
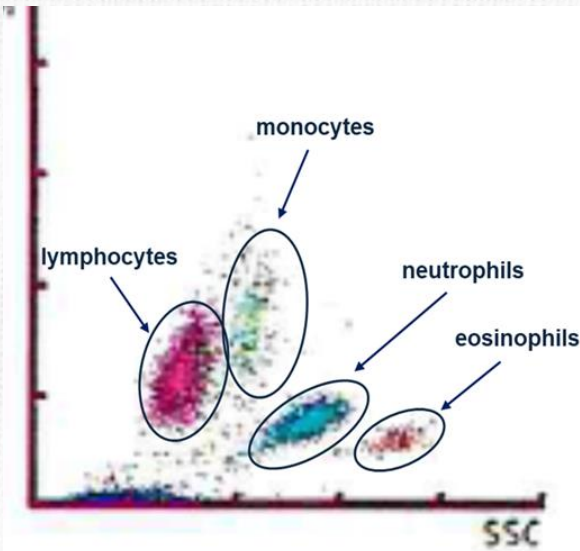
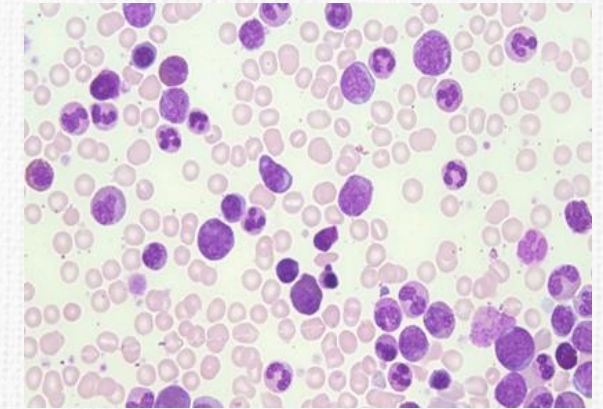
WBC IP Message
WBC Abn Scattergram
Neutrophilia
Lymphocytosis
Monocytosis
Eosinophilia
Basophilia
Leukocytosis
IG Present
Blasts/Abn Lympho?
Left Shift?

RBC IP Message
Anisocytosis
Anemia
Turbidity/HGB Interf?
iRBC?

PLT IP Message
PLT Clumps?




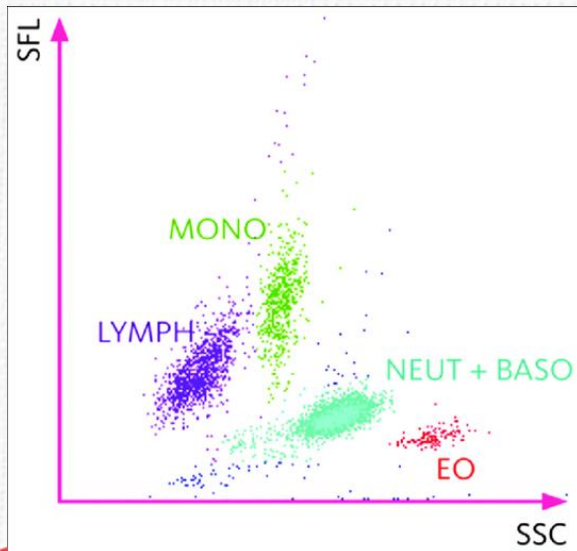
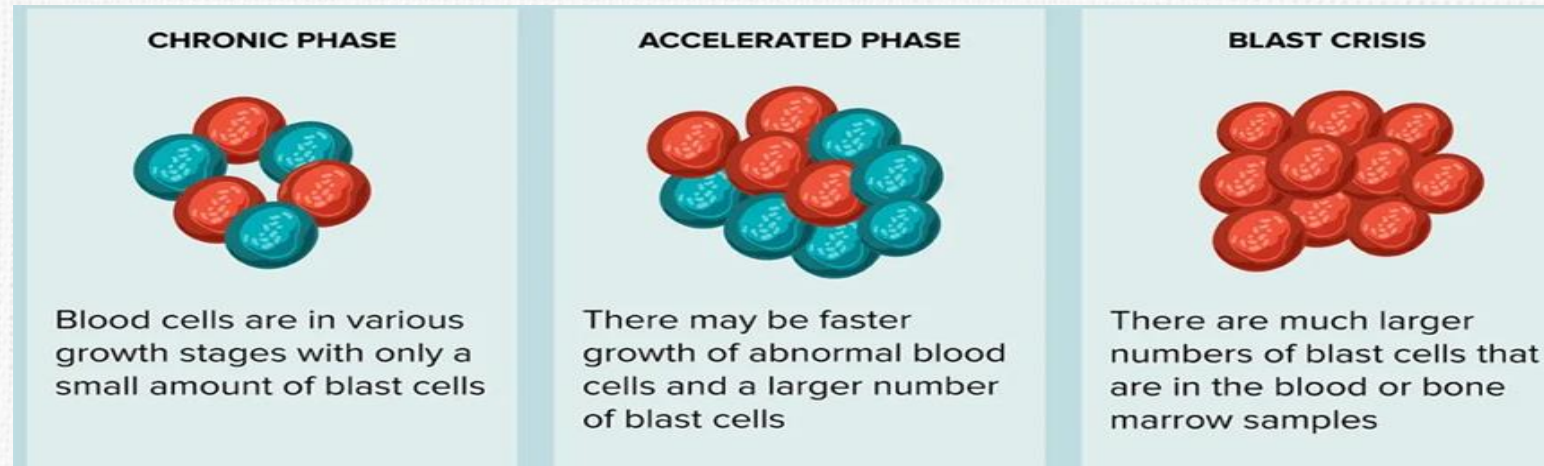
- **CBC** Αυξημένα λευκά, 612,810/ μl,
- Αυξημένα ουδετερόφιλα 562,840/ μl
- Κατανομή ιστογράμματος? Αριστερή στροφή
- **Μορφολογία:** Αυξημένα ώριμα ουδετερόφιλα



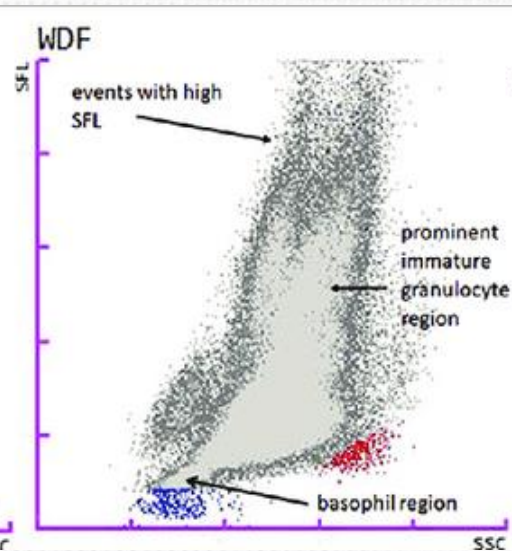
Απεικονίσεις από Χρόνια Μυελογενή Λευχαιμία (CML) στον αναλυτή

3 phases of CML:

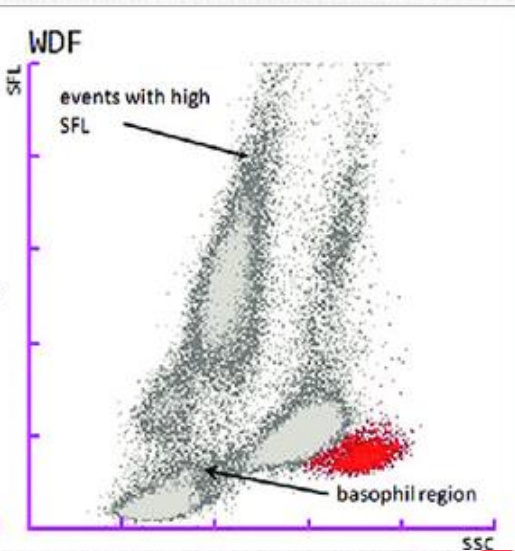
1. Chronic Phase
2. Accelerated Phase
3. Blast Phase (Blast crisis)



CML-Chronic phase: expanded myelocyte, metamyelocyte, bands



CML-Accelerated Phase



CML-Blast Phase